

Vol III Issue VII April 2014

ISSN No : 2249-894X

*Monthly Multidisciplinary
Research Journal*

*Review Of
Research Journal*

Chief Editors

Ashok Yakkaldevi
A R Burla College, India

Flávio de São Pedro Filho
Federal University of Rondonia, Brazil

Ecaterina Patrascu
Spiru Haret University, Bucharest

Kamani Perera
Regional Centre For Strategic Studies,
Sri Lanka

Welcome to Review Of Research

RNI MAHMUL/2011/38595

ISSN No.2249-894X

Review Of Research Journal is a multidisciplinary research journal, published monthly in English, Hindi & Marathi Language. All research papers submitted to the journal will be double - blind peer reviewed referred by members of the editorial Board readers will include investigator in universities, research institutes government and industry with research interest in the general subjects.

Advisory Board

Flávio de São Pedro Filho Federal University of Rondonia, Brazil	Horia Patrascu Spiru Haret University, Bucharest, Romania	Mabel Miao Center for China and Globalization, China
Kamani Perera Regional Centre For Strategic Studies, Sri Lanka	Delia Serbescu Spiru Haret University, Bucharest, Romania	Ruth Wolf University Walla, Israel
Ecaterina Patrascu Spiru Haret University, Bucharest	Xiaohua Yang University of San Francisco, San Francisco	Jie Hao University of Sydney, Australia
Fabricio Moraes de Almeida Federal University of Rondonia, Brazil	Karina Xavier Massachusetts Institute of Technology (MIT), USA	Pei-Shan Kao Andrea University of Essex, United Kingdom
Catalina Neculai University of Coventry, UK	May Hongmei Gao Kennesaw State University, USA	Loredana Bosca Spiru Haret University, Romania
Anna Maria Constantinovici AL. I. Cuza University, Romania	Marc Fetscherin Rollins College, USA	Ilie Pinte Spiru Haret University, Romania
Romona Mihaila Spiru Haret University, Romania	Liu Chen Beijing Foreign Studies University, China	
Mahdi Moharrampour Islamic Azad University buinzahra Branch, Qazvin, Iran	Nimita Khanna Director, Isara Institute of Management, New Delhi	Govind P. Shinde Bharati Vidyapeeth School of Distance Education Center, Navi Mumbai
Titus Pop PhD, Partium Christian University, Oradea, Romania	Salve R. N. Department of Sociology, Shivaji University, Kolhapur	Sonal Singh Vikram University, Ujjain
J. K. VIJAYAKUMAR King Abdullah University of Science & Technology, Saudi Arabia.	P. Malyadri Government Degree College, Tandur, A.P.	Jayashree Patil-Dake MBA Department of Badruka College Commerce and Arts Post Graduate Centre (BCCAPGC), Kachiguda, Hyderabad
George - Calin SERITAN Postdoctoral Researcher Faculty of Philosophy and Socio-Political Sciences Al. I. Cuza University, Iasi	S. D. Sindkhedkar PSGVP Mandal's Arts, Science and Commerce College, Shahada [M.S.]	Maj. Dr. S. Bakhtiar Choudhary Director, Hyderabad AP India.
REZA KAFIPOUR Shiraz University of Medical Sciences Shiraz, Iran	Anurag Misra DBS College, Kanpur	AR. SARAVANAKUMARALAGAPPA UNIVERSITY, KARAIKUDI, TN
Rajendra Shendge Director, B.C.U.D. Solapur University, Solapur	C. D. Balaji Panimalar Engineering College, Chennai	V.MAHALAKSHMI Dean, Panimalar Engineering College
	Bhavana vivek patole PhD, Elphinstone college mumbai-32	S.KANNAN Ph.D , Annamalai University
	Awadhesh Kumar Shirotriya Secretary, Play India Play (Trust), Meerut (U.P.)	Kanwar Dinesh Singh Dept.English, Government Postgraduate College , solan

More.....

Address:-Ashok Yakkaldevi 258/34, Raviwar Peth, Solapur - 413 005 Maharashtra, India
Cell : 9595 359 435, Ph No: 02172372010 Email: ayisrj@yahoo.in Website: www.ror.isrj.net



BEHAVIOURAL AND HISTOLOGICAL CHANGES INDUCED BY CADMIUM CHLORIDE ON ALIMENTARY TRACT OF FRESHWATER FISH, *TILAPIA MOSSAMBICA (PETERS)*

Meenakshi Sundaresan

Department of Zoology, D.G. Ruparel College, Mahim, Mumbai, India.

Abstract:

*The present work deals with Cadmium induced behavioral and histological changes in the alimentary tract of *Tilapia mossambica* (Peters). The fish were exposed to sub lethal concentration of 8 ppm Cadmium chloride for 6 and 22 days. Sections of buccal epithelium, stomach, intestine and rectum of control and treated fish were stained with H/E and Giemsa and studied for histological purposes. Treatment induced changes observed include overall thinning of the wall of alimentary canal leading to loss of tubular nature, separation of the mucosa layer from the underlying tissue, desquamation of the epithelial lining and the isolation of epithelial cells etc. Occurrence of cytoplasmic vacuoles and tearing of the epithelial layer is quite frequent. Loss of villar tips in the intestine and increase in the number of lymph glands in the rectum are the other noticeable changes. Occurrence and the extent of such changes are proportional to the dosages of treatment and also to the period of exposure.*

KEY WORDS:

Tilapia mossambica, alimentary canal, cadmium chloride, histological changes

INTRODUCTION

Urbanization and large scale industrialization has resulted in water pollution. Effluents discharged from the industries contain a vast variety of pollutants such as pesticides, detergents, petroleum products and salts of heavy metal. These pollutants, on entering water resources, severely affect the aquatic forms including fishes. Fishes are widely used to evaluate the health of aquatic ecosystems (Yousuf and El-shahawi, 1999; Farkas *et al*, 2002). Of all the pollutants that are responsible for water pollution, salts of heavy metals are of much importance and are constantly reviewed since they are non-degradable and hence bio-accumulate in the food chain (Meenakshi Sundaresan and S.V. Shanbhag, 2009; Nuntiya Pantung *et al*, 2008; Van Dyk *et al*, 2007; Athikesaven *et al*, 2006; Rangsayatorn *et al*, 2004; Thopon S. *et al*, 2003, 2004).

In the present study, the cichlid fish *Tilapia mossambica* (Peters) has been used to study the effects of Cadmium chloride on the various tissues of its alimentary canal. The general details of the histological structure of control and treated fish have been studied to evaluate the effect of cadmium chloride.

MATERIALS AND METHODS

Experimental fish, *Tilapia mossambica* (Peters) were collected from Masunda lake situated in Thane. They were acclimatized in the laboratory for a period of two weeks. Subsequently the fishes were grouped in two batches of twenty each, one set control and the other treated with effective sublethal dosage

Title: " BEHAVIOURAL AND HISTOLOGICAL CHANGES INDUCED BY CADMIUM CHLORIDE ON ALIMENTARY TRACT OF FRESHWATER FISH, *TILAPIA MOSSAMBICA (PETERS)* ", Source: Review of Research [2249-894X] Meenakshi Sundaresan yr:2014 | vol:3 | iss:7

BEHAVIOURAL AND HISTOLOGICAL CHANGES INDUCED BY CADMIUM CHLORIDE.....

of 8 ppm Cadmium chloride exposed for 6 and 22 days. They were fed on live tubifex worms on alternate days. To maintain the concentration of the toxicant, the test water was changed every 24 hrs. Tanks were aerated with oil free air and test water quality was evaluated employing standard methods (APHA 1985). Behavioural changes in the fishes were noted during the treatment. Fishes from both tanks- control and treated (after 6 and 22 days), were sacrificed and tissues were collected for histological preparations. Tissues collected for the purpose include buccal epithelium, stomach, intestine and rectum part of the alimentary canal. Tissues were fixed in Neutral formalin and chilled alcohol and sections of control and treated fish were stained with Giemsa, Toluidine Blue and Haematoxylin/Eosin (Gurr E., 1956).

RESULTS AND OBSERVATIONS

Behavioural changes: The immediate response of the fish to Cadmium chloride treatment was found to be its violent and jerky movements. This was followed by increased rate of opercular movements. Prolonged treatment lead to lethargic behaviour, low rate of feeding and the fishes failed to respond even when they were probed. They preferred to remain at the bottom seeking a dark corner.

Histological changes: The tubular nature of the alimentary canal is lost and this is followed by the flattening of the tube. The wall of the alimentary canal of the treated fish appears to be thinner than that of control fish. The buccal epithelium of the normal fish shows the following regions (from the interior to the exterior) – 1) Epithelial lining, 2) Basement membrane, 3) Underlying connective tissue and 4) Supporting muscle (Fig. 1 & 2).

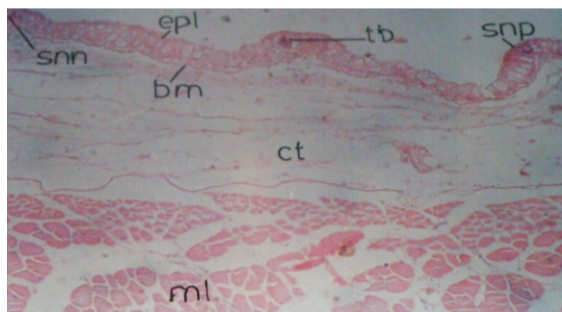


Fig. 1: V.S. of Buccal epithelium (control fish) showing various layers Stain H/E

epl - Epithelial lining, bm– basement membrane, ct– connective tissue, ml – muscle layer, snp – sensory papilla, tb – taste bud, snn– sensory nerve

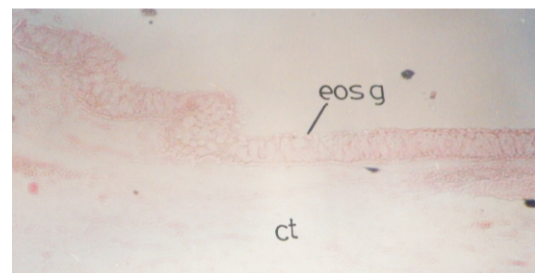


Fig. 2: V.S. of Buccal epithelium (treated fish 8ppm, 22 days). Eosinophilic granules are seen at free edges. The cells are seen in contracted condition Stain H/E

eosg – Eosinophilic granules, ct– connective tissue

In the treated fish the epithelial cells have reduced heights. The epithelial lining of the buccal region is often vacuolated and gives a nodular appearance. The sensory papillae borne over the epithelial lining lose their proper filamental shape and become broad and irregular. Taste buds too get affected and lose their flask shaped feature (Fig. 3 & 4).

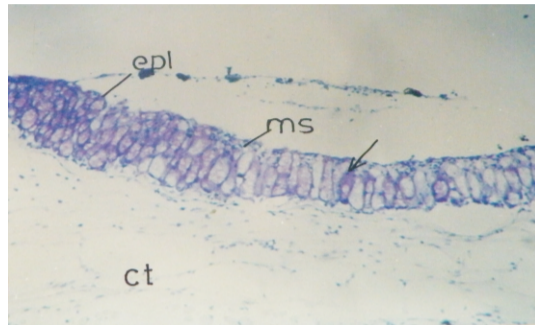


Fig. 3: V.S. of Buccal epithelium (control fish) Stain: Toluidine Blue

epl - Epithelial lining, ms- mucous secretion, ct - connective tissue mucous secretory cell

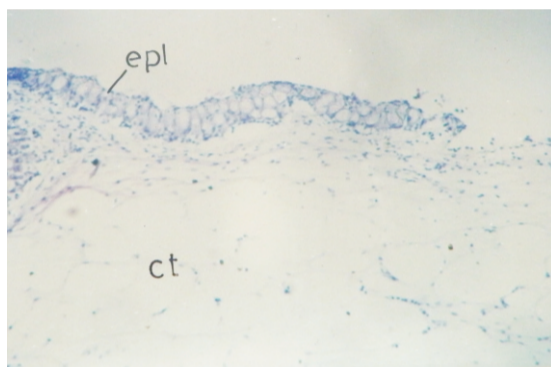


Fig. 4: V.S. of Buccal epithelium (treated fish 8ppm, 22 days). Epithelial cells contracted and intensity of stain reduced. Stain: Toluidine Blue

epl - Epithelial lining, ct- connective tissue

Sections of stomach (in control fish) appear circular. The wall of the stomach has 4 layers, viz., serosa, muscularis, submucosa and mucosa. The mucosa layer is thrown into several folds (gastric folds) which extend into the stomach. The submucosa layer also traverses into it to form the stroma (Fig. 5 & 6).

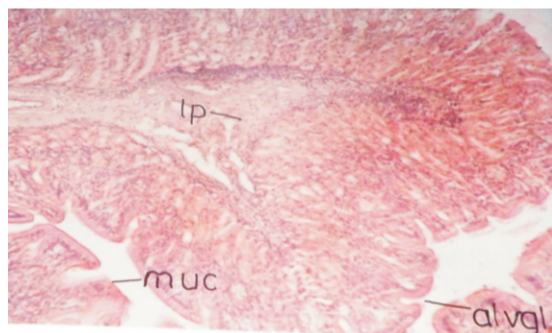


Fig. 5: T.S. of Stomach (control fish) Stain: H/E

lp- lamina propia, muc- mucosa, alvgl - alveolar gland

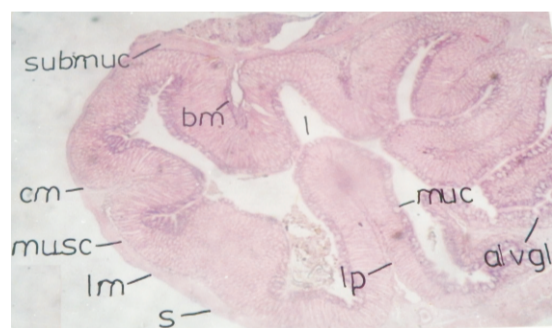


Fig. 6: T.S. of Stomach (control fish) Stain: H/E

s- serosa, musc- muscularis, bm - basement membrane, l- lumen, lm - longitudinal muscle layer, cm - circular muscle layer, lp- lamina propia, muc- mucosa, alvgl- alveolar gland

In treated fish, thickness of the stomach wall is greatly reduced. This is mainly due to the loss of the muscular layer over the outer extremity and also due to the contraction of the mucosa lining. Serosa is totally lacking and so also the longitudinal muscles. Submucosa region is also reduced. Mucosa is greatly affected and is characterized by the great reduction in the size of the gastric folds. There is a remarkable

reduction in the cell heights. Alveolar glands give a shrunken appearance and striated cells get separated. The other changes include appearance of cytoplasmic vacuoles at various sites (Fig. 7).

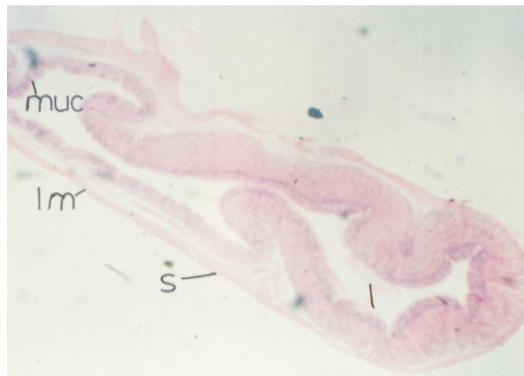


Fig. 7: T.S. of Stomach (treated fish, 8ppm 22 days) Stain: H/E. Flattening of the tube, reduction of the height of gastric fold. Thinning and separation of wall layers are observed.

s- serosa, l- lumen, lm- longitudinal muscle layer, muc- mucosa

The intestine of normal fish has an outer layer, serosa. Muscularis layer is prominent and occupies 50% of the wall thickness except for the region of villi. Muscular layer consists of outer longitudinal muscle and inner circular muscles. Submucosa is fairly thick, compact layer consisting of connective tissue cells, fibres and blood vessels. In the region of the villi, this tissue extends interiorly to form the stroma. Mucosa is prominent and gives rise to villi like projections (Fig. 8).

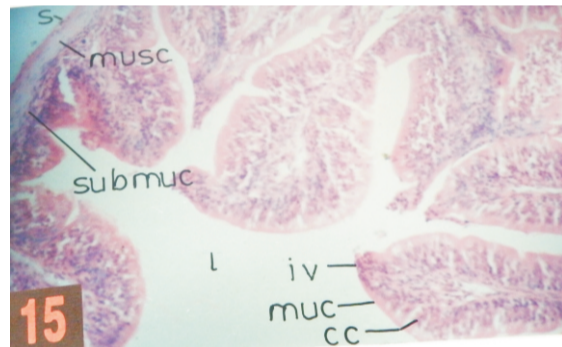


Fig. 8: T.S. of Intestine (control fish) Stain: H/E. Wall is thin and presence of villi is characteristic.

s- serosa, musc- muscularis, muc- mucosa, submuc- submucosa, l- lumen, iv- intestinal villi, cc- chief cells

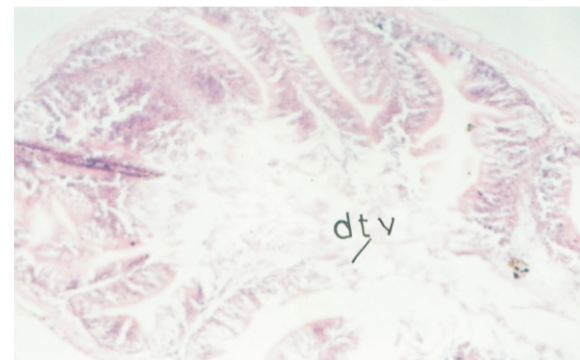


Fig. 9: T.S. of Intestine (treated fish, 8ppm 22 days) Stain: H/E. Wall is thickened and villar tips undergo degeneration

dtv - degenerated tips of villi

The intestinal region of the treated fish is characterized by the reduction in the heights of the villi. Tips of the villi are often totally degenerated exhibiting a kind of discontinuity of the mucosa layer. Cracking of the epithelial lining and the appearance of the cytoplasmic granules are the other features observed in the treated form (Fig. 9 & 10).

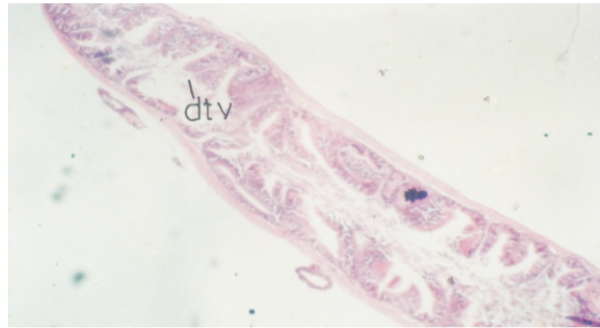

Fig. 10: T.S. of Intestine (treated fish, 8ppm 22 days) Stain: H/E. Wall is thinned and villar tips undergo degeneration.
dtv – degenerated tips of villi

Sections of rectum in control fish represent all the usual layers, viz., serosa, muscularis, submucosa and mucosa. Serosa is seen distinctly over the outer extremity. Longitudinal muscle layer is quite prominently seen. In between the longitudinal and circular layers there are lymph glands arranged continuously in the form of a row. Submucosa is comparatively thin except for the region of mucosal folds. It consists of connective tissue fibres and the cells. Mucosal region occupies one-fifth of the total thickness. It is thrown into folds. The epithelial cells lining the mucosa are high, columnar with their basal ends narrow. The border free edges are full of fine eosinophilic granules because of which the entire region appears pink. Also contain larger unstained regions at their inner ends which are either glycogen cells or chief cells. Such spaces are either oval or spherical in shape (Fig. 11 & 12). Rectum of the treated fish is characterized by a great reduction in wall thickness. Serosa is present but appears discontinuous. Serosa lining has several nodular swellings. The presence of these attribute a wavy look to the outer wall. Several vacuoles are also noticeable in this region. Muscular layer of the rectal wall is very thinned out and separated from the underlying serosa layer. Lymph glands however are seen very prominently.

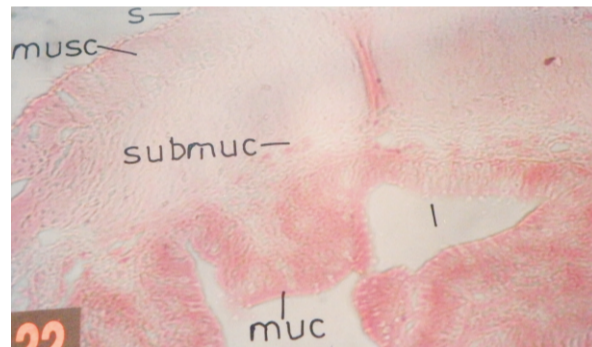


Fig. 11: T.S. of rectum (control fish) Stain: H/E.
s – serosa, musc – muscularis, muc – mucosa, submuc – submucosa, l – lumen

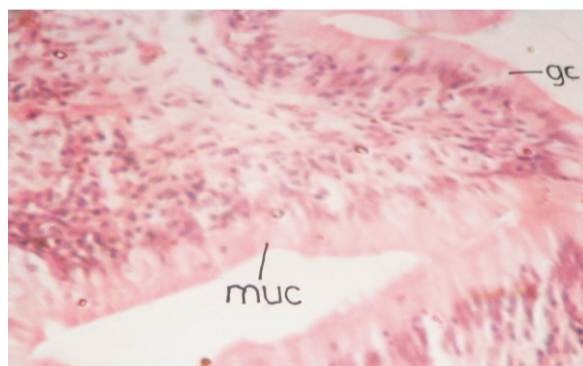


Fig. 12: T.S. of rectum (control fish) Magnified. Stain: H/E.
muc – mucosa, gc – glycogen cells

Submucosa layer is also obliterated and shows presence of several vacuolar spaces. Desquamatisation of the rectal mucosa is greatly evident. The epithelial cells are highly disrupted and the inner edges of the mucosa lining are often lost giving a wavy look to the margin. The epithelial cells being

separated from each other, intercellular spaces are seen at various places. Vacuoles are also seen within the cytoplasm (Fig. 13 & 14).

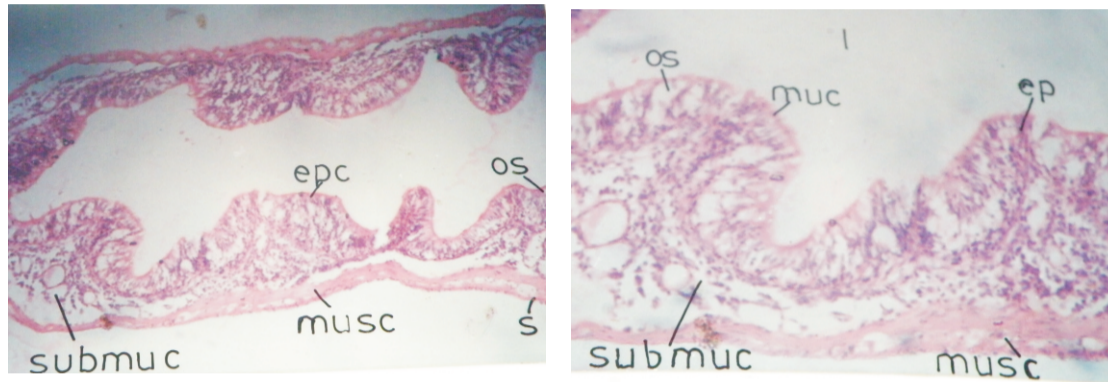


Fig. 13 & 14: T.S. of rectum (treated fish, 8ppm 22 days). Stain: H/E. Thickness of longitudinal and circular muscles reduced, submucosa separated from muscularis. Large oval spaces in between the epithelial cells.

muc – mucosa, submuc – submucosa, l – lumen, os – oval spaces, epc – epithelial cells, musc – muscularis

DISCUSSION

Fishes are the organisms that are easily prone to the detrimental effects of pollutants (Puneet Kumar and Anu Singh, 2010; Okacha R.C. and Adedeji O.B., 2011). Cadmium is one such heavy metal pollutant found in aquatic ecosystems. The main effects of Cadmium chloride on the alimentary canal of the fish include loss of tubular nature and thinning of the wall. Similar effects have been reported by previous workers (Pai Vinaya L., 1993; Uttam Kr Sen and Apurba Ratan Ghosh, 2008). These changes may not be directly caused by the pollutant but could be attributed to the low feeding of the fishes during treatment. The low feeding possibly leads to the utilization of tissue stored material. This possibly could be the cause for the thinning of the wall and subsequent deshaping of the alimentary canal.

The reduction in the height of the mucosal lining, appearance of vacuoles in the region as well as the subsequent disruption of the lining is definitely caused because of the direct contact with the chemical that is used. Looseness of the epithelial cells, appearance of vacuoles in between the cells and similarly the reduced heights of gastric folds are the direct effects. The study has shown that these effects are much more evident in the rectal region than in any other region of the alimentary canal. This is obviously for the reason that the chemical substance that is used gains entry into the alimentary canal and is stored in the rectal region for a considerable period before its discharge to the exterior and it is this prolonged contact of the wall with the material that aggravates the situation.

The histological changes such as thinning of the wall, reduction in size of mucosal cells, separation of the mucosa layer from the basement membrane, appearance of cytoplasmic vacuoles and the loss of serosa lining etc are some of the changes that are observed throughout the length of the alimentary canal; although the extent of damage caused differs in different regions. Of these, contractions of the cells and the separation of the mucosa layer from the basement membrane appear to be the immediate effects that are introduced owing to the direct contact of the cells with the Cadmium salt. The other effects such as appearance of vacuoles and separation of individual cells seem to be introduced subsequently. The reason for the separation of the serosa layer, the outermost layer of the digestive tube which never comes in direct contact with the pollutant is not clear. Its degeneration however is evident in all the regions of the alimentary canal.

Some of the changes observed in the different regions of the alimentary canal with possible explanations for the changes are as under:

Buccal epithelium: The animal has to take in water through its mouth for the purpose of respiration. For the purpose the treated (Cadmium chloride) water comes in constant contact with the

BEHAVIOURAL AND HISTOLOGICAL CHANGES INDUCED BY CADMIUM CHLORIDE.....

epithelial lining of the buccal cavity. The desquamation of the epithelial lining as well as loss of shape of the papillae are the sure signs of effects. Appearance of gaps between the adjacent cells is another feature which is caused because of the treatment.

Stomach: Besides the usual effects discussed commonly for the alimentary canal the other effects that are strikingly evident in the region are the effects that are observed on the gastric and alveolar glands. There is a distinct reduction in the heights of the gland cells. Besides cells of the gastric glands gets separated from each other. The appearance of cytoplasmic vacuoles is another change that is clearly evident.

Intestine: Histological changes observed in the intestinal region are the loss of villar tips, the separation of the epithelial lining from the basement membrane and the loss of epithelial cells including the gland cells (Shastry K.V. and Gupta P.K., 1979; Kruatrachue M. et al. 2003; Vesey D.A., 2010).

Rectum: Degenerative changes are much more evident in the rectal region than in any other region. Here too it is the epithelial lining that is affected to a great extent.

ACKNOWLEDGEMENTS

Author is grateful to Dr. S.V. Shanbhag for providing valuable guidance and encouragement for this research.

REFERENCES

1. APHA (1985) 'Standard methods for the examination of water and waste water' APHA/ AWWA / WPCF, Washington DC, USA
2. Athikesavan S., Vincent S., Ambrose T., Velmurugan B. (2006) Nickel induced histopathological changes in the different tissues of the freshwater fish *Hypophthalmichthys molitrix* (valenciennes) J. Environ. Biol. 27: 391-395.
3. Farkas A.J., Salanki, A. Specziar (2002). Relation between growth and heavy metal concentration in organs of bream *Abramis brama* L. populating lake Balaton. Arch. Environ. Contam. Toxicol. 43 (2): 236-243.
4. Gurr E. (1956) A Practical manual of medical and biological staining techniques. Leonard Hill (Books) Ltd. London.
5. Kruatrachue M. Rangsayatorn N, Pokethitiyook P., Upathan E.S. and Singhakaeco S. (2003) Histological changes in the gastrointestinal tract of fish, *Puntius gonionotus*, fed on dietary cadmium. Bulletin of Environmental Contamination and Toxicology. 7: 0561-0569.
6. Meenakshi Sundaresan and S.V. Shanbhag. (2009). Effect of cadmium on the blood of *Tilapia mossambica* (Peters) J. Aqua. Biol. 24: 193-198.
7. Nuntiya Pantung, Kerstin G. Helander, Herbert F. Helander and Vorabit Cheevaporm. (2008). Histopathological alterations of hybrid walking catfish (*Clarias macrocephalus* x *Clarias gariepinus*) in acute and sub-acute cadmium exposure. Environ. Asia 22-27.
8. Okacha R.C. and Adedeji O.B. (2011) Overview of cadmium toxicity in fish. Journal of Applied Sciences Research. 7(7): 1195-1207.
9. Pai Vinaya L. (1993). On certain histological aspects of fishes, PhD Thesis submitted to university of Bombay.
10. Puneet Kumar and Anu Singh (2010) Cadmium toxicity in fish: An overview. GEF Bulletin of Biosciences. 1(1): 41-47.
11. Rangsayatorn N., Kruatrachue M., Pokethitiyook P., Upathan ES, Lanza GR, Singhakaeco S. (2004). Ultrastructural changes in various organs of the fish *Puntius gonionotus* fed cadmium enriched cyanobacteria. Environ. Toxicol. 19: 585-93.
12. Thopon S., Kruatrachue M., Upatham ES, Pokethitiyook P., Sahaphong S., Jaritkhuan S. (2003) Histopathological alterations of white sea bass, *Lates calcarifer* in acute and sub-chronic cadmium exposure. Environ. Poll. 121: 307-20.
13. Thopon S., Pokethitiyook P., Chalermwat K., Upatham ES, Sahaphong S. (2004) Ultrastructural alterations in the liver and kidney of white sea bass, *Lates calcarifer* in acute and sub-chronic cadmium exposure. Environ. Toxicol. 19: 11-19.
14. Uttam Kr Sen and Apurba Ratan Ghosh, (2008). Histological and ultramicroscopical alterations in the regions of gastro intestinal tracts of *Anabas testudineus* (bloch) induced by cadmium chloride. Poll. Res. 27 (4): 699-703.
15. Van Dyk J.C., Pieterse G.M., Van Vuren J.H. (2007) Histological changes in the liver of *Oreochromis*

BEHAVIOURAL AND HISTOLOGICAL CHANGES INDUCED BY CADMIUM CHLORIDE.....

- mossambicus (cichlidae) after exposure to cadmium and zinc. *Ecotox. and Environ. Safety*. 66: 432-40.
16. Vesey D.A. (2010) Transport pathways for cadmium in the intestine and kidney proximal tubules - Focus on the interaction with essential metals. *Toxicol. Letters*. 198(1): 13-19.
17. Yousuf M. H. A. and M.S. El-shahawi, (1999) Trace metals in *Lethrinus lentjan* fish from Arabian Gulf. Metal accumulation in kidney and heart tissues. *Bull. Environ. Contam. Toxicol.* 62 (3): 293-300.



Meenakshi Sundaresan

Department of Zoology, D.G. Ruparel College, Mahim, Mumbai, India.

Publish Research Article International Level Multidisciplinary Research Journal For All Subjects

Dear Sir/Mam,

We invite unpublished Research Paper, Summary of Research Project, Theses, Books and Books Review for publication, you will be pleased to know that our journals are

Associated and Indexed, India

- ★ Directory Of Research Journal Indexing
- ★ International Scientific Journal Consortium Scientific
- ★ OPEN J-GATE

Associated and Indexed, USA

- DOAJ
- EBSCO
- Crossref DOI
- Index Copernicus
- Publication Index
- Academic Journal Database
- Contemporary Research Index
- Academic Paper Database
- Digital Journals Database
- Current Index to Scholarly Journals
- Elite Scientific Journal Archive
- Directory Of Academic Resources
- Scholar Journal Index
- Recent Science Index
- Scientific Resources Database

Review Of Research Journal
258/34 Raviwar Peth Solapur-413005, Maharashtra
Contact-9595359435
E-Mail-ayisrj@yahoo.in/ayisrj2011@gmail.com
Website : www.ror.isrj.net